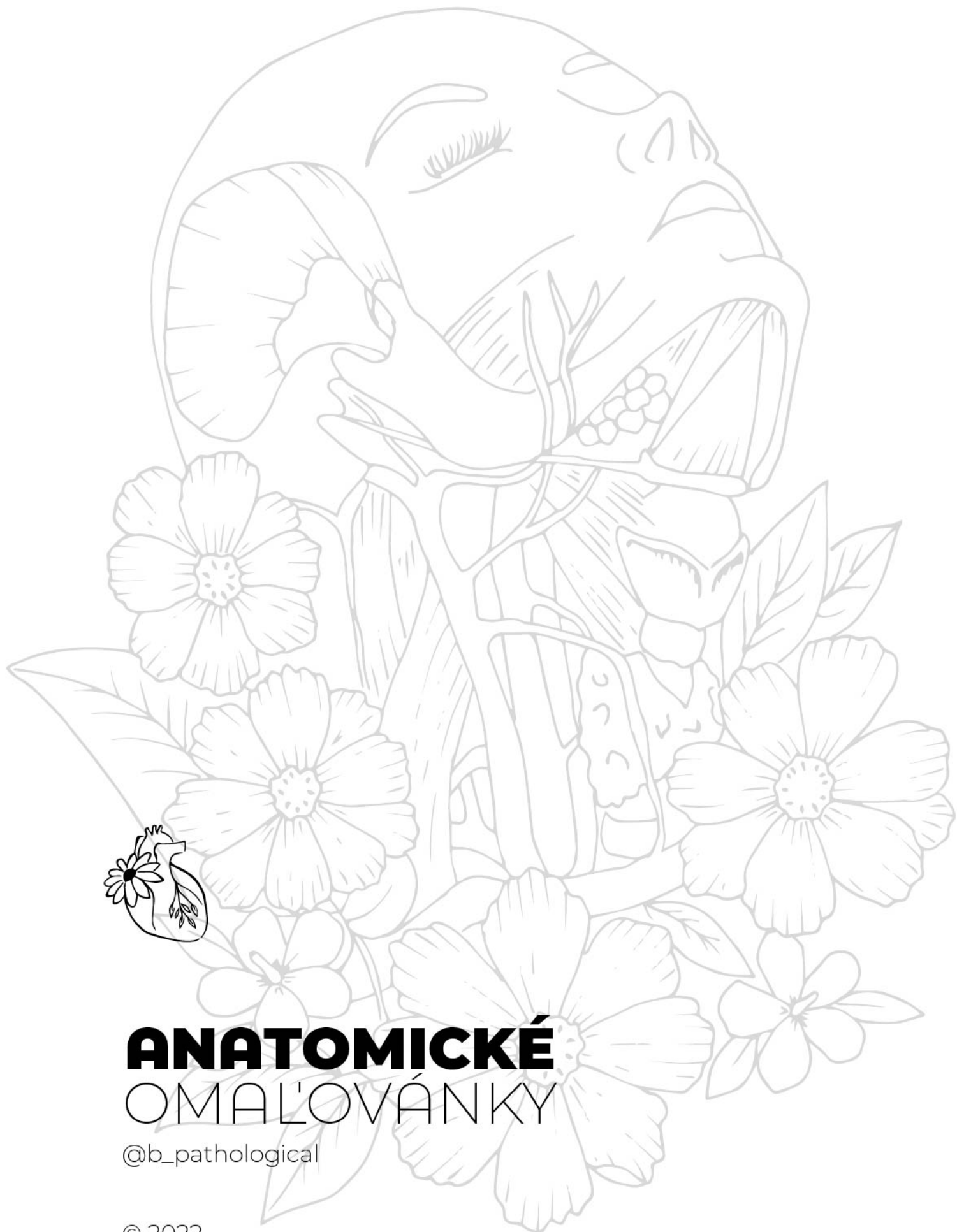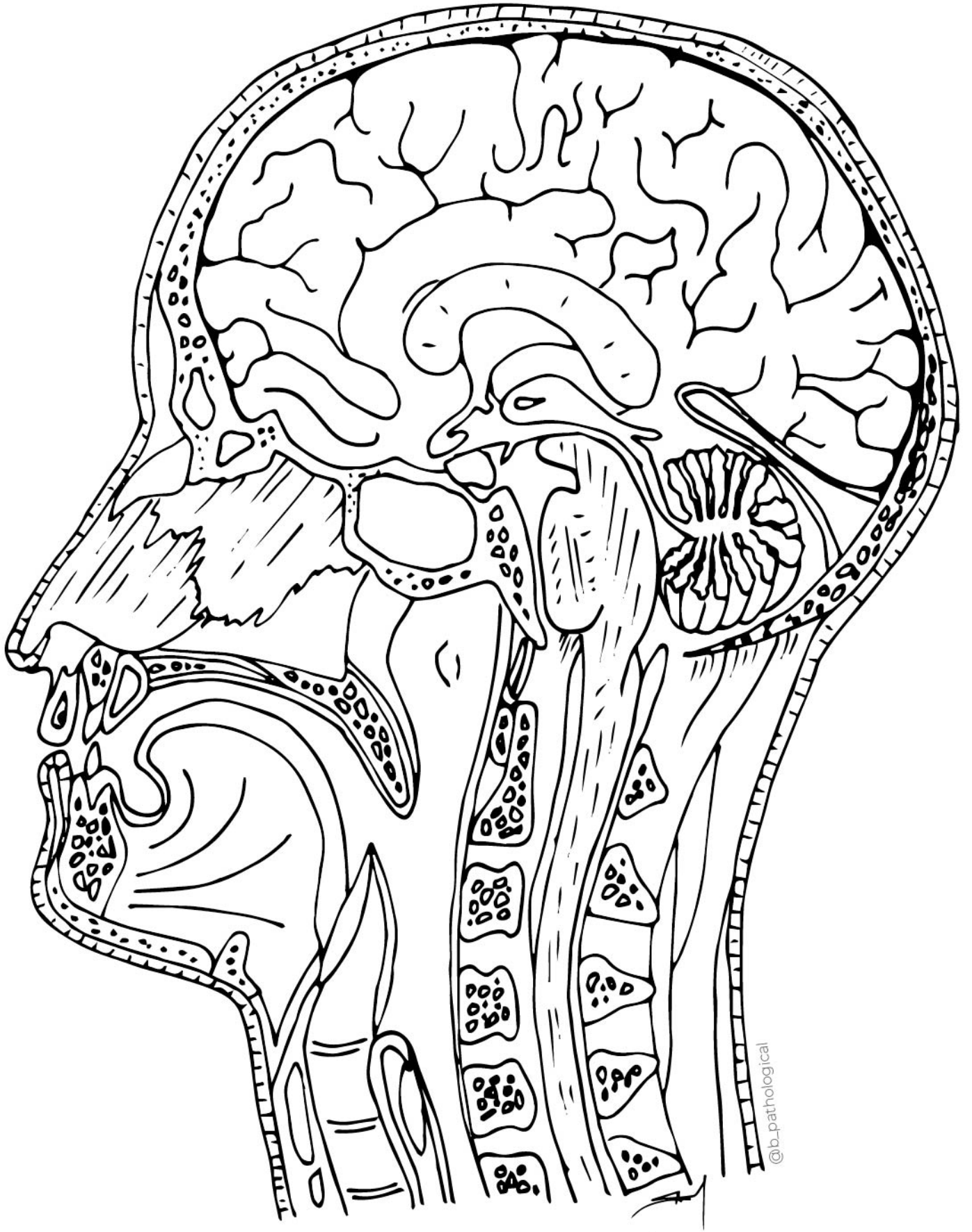
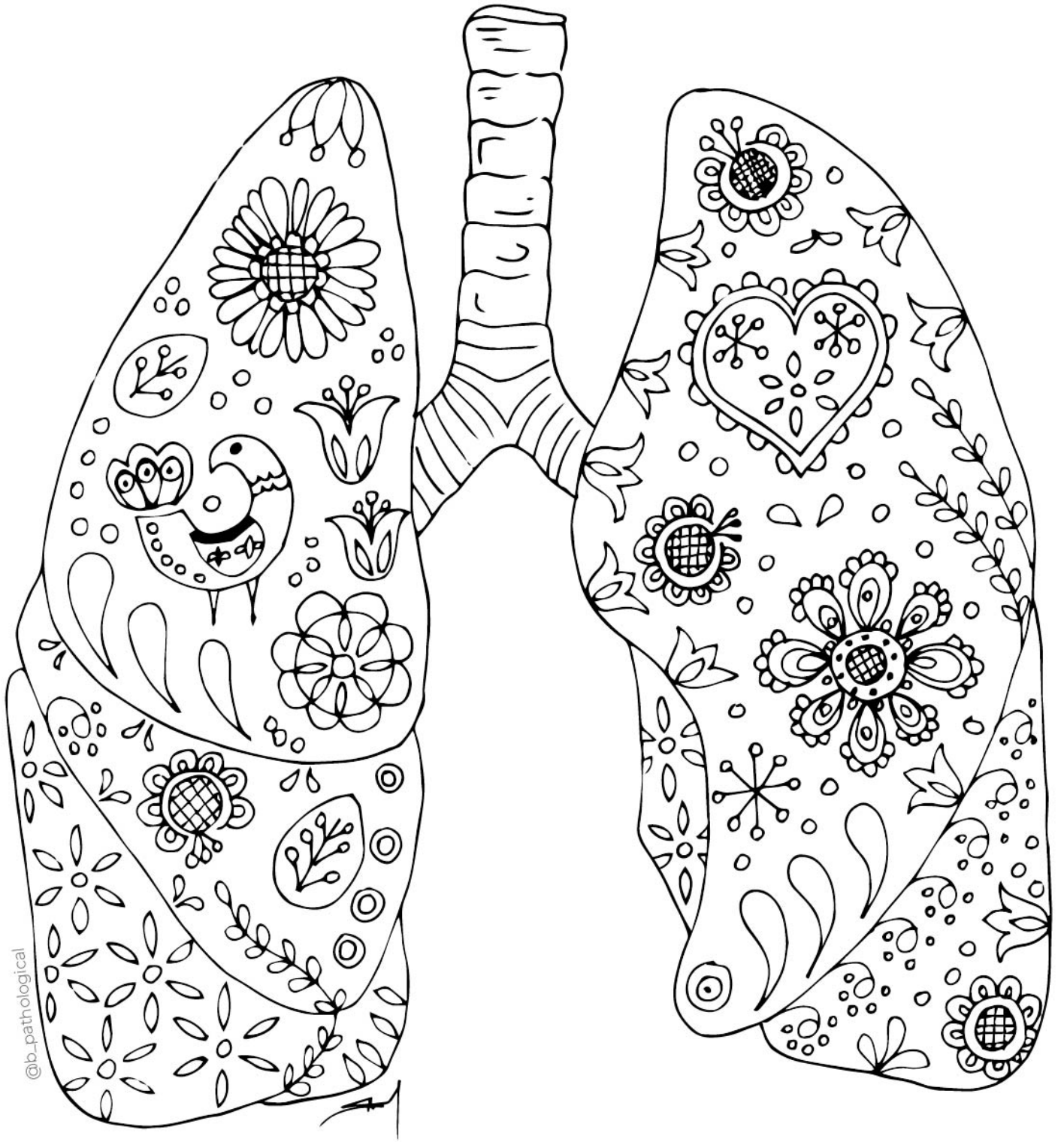


# ANATOMICKÉ OMALOVÁNKY

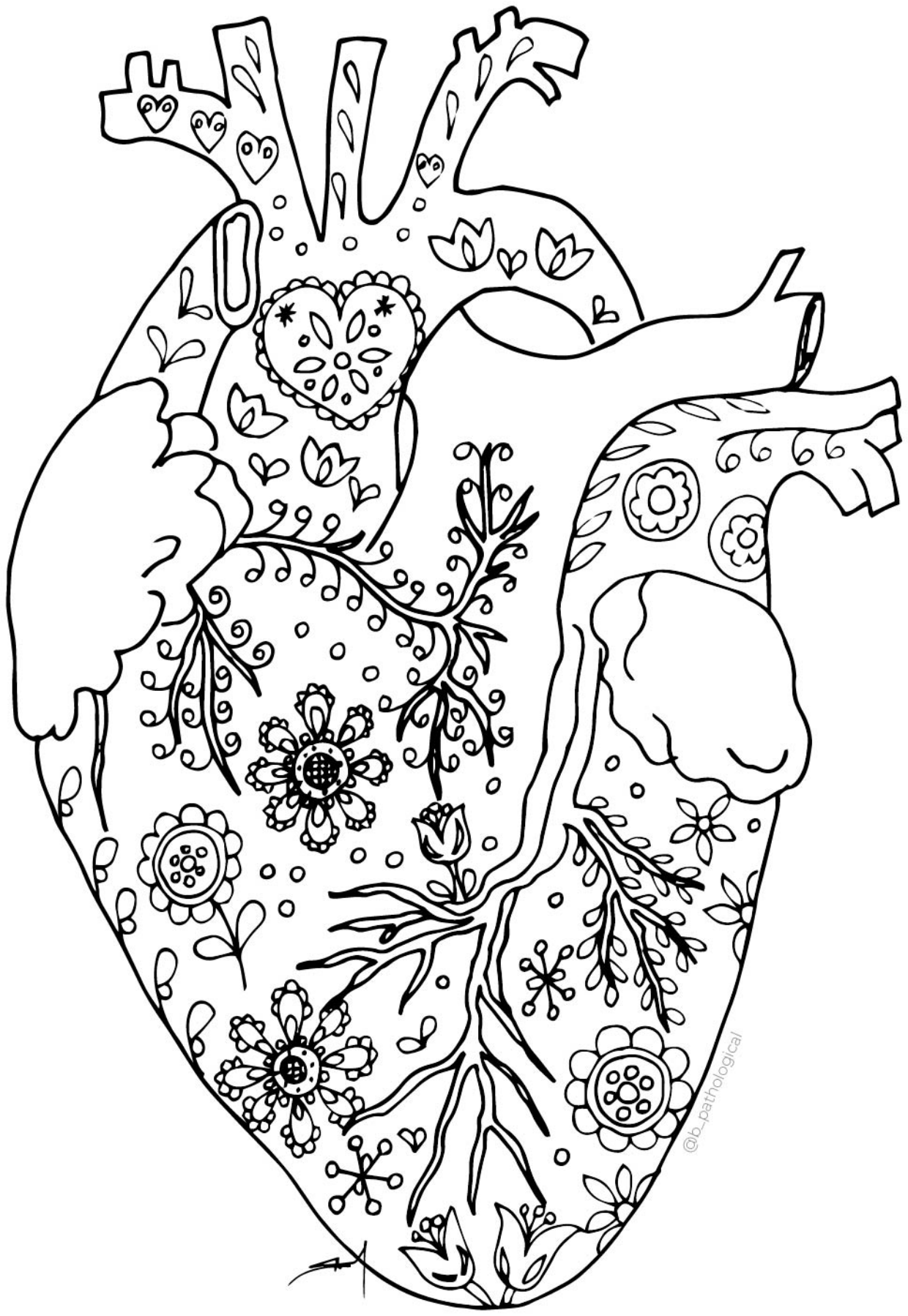
@b\_pathological

© 2022






@b\_pathological



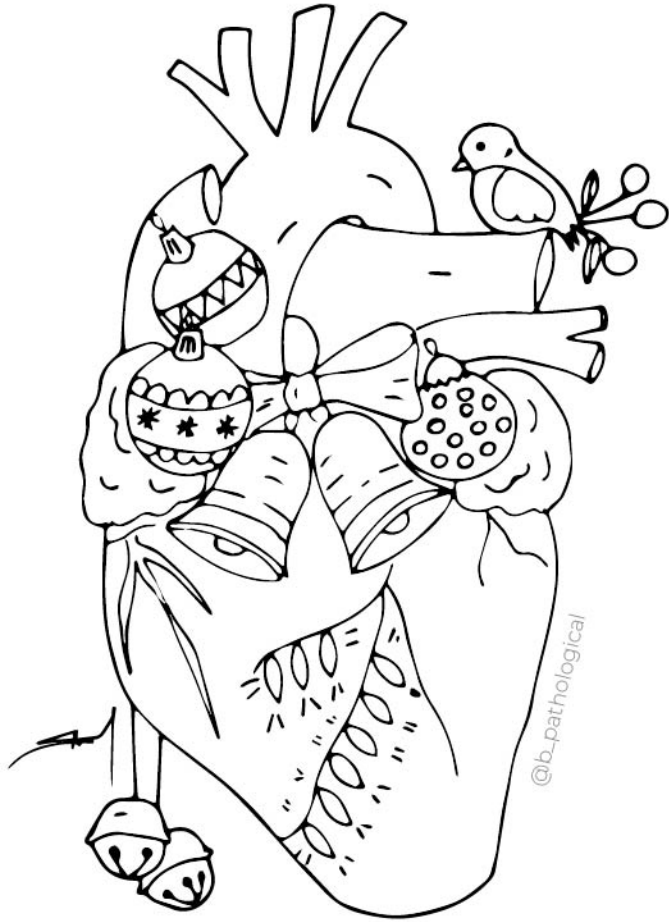@b\_pathological

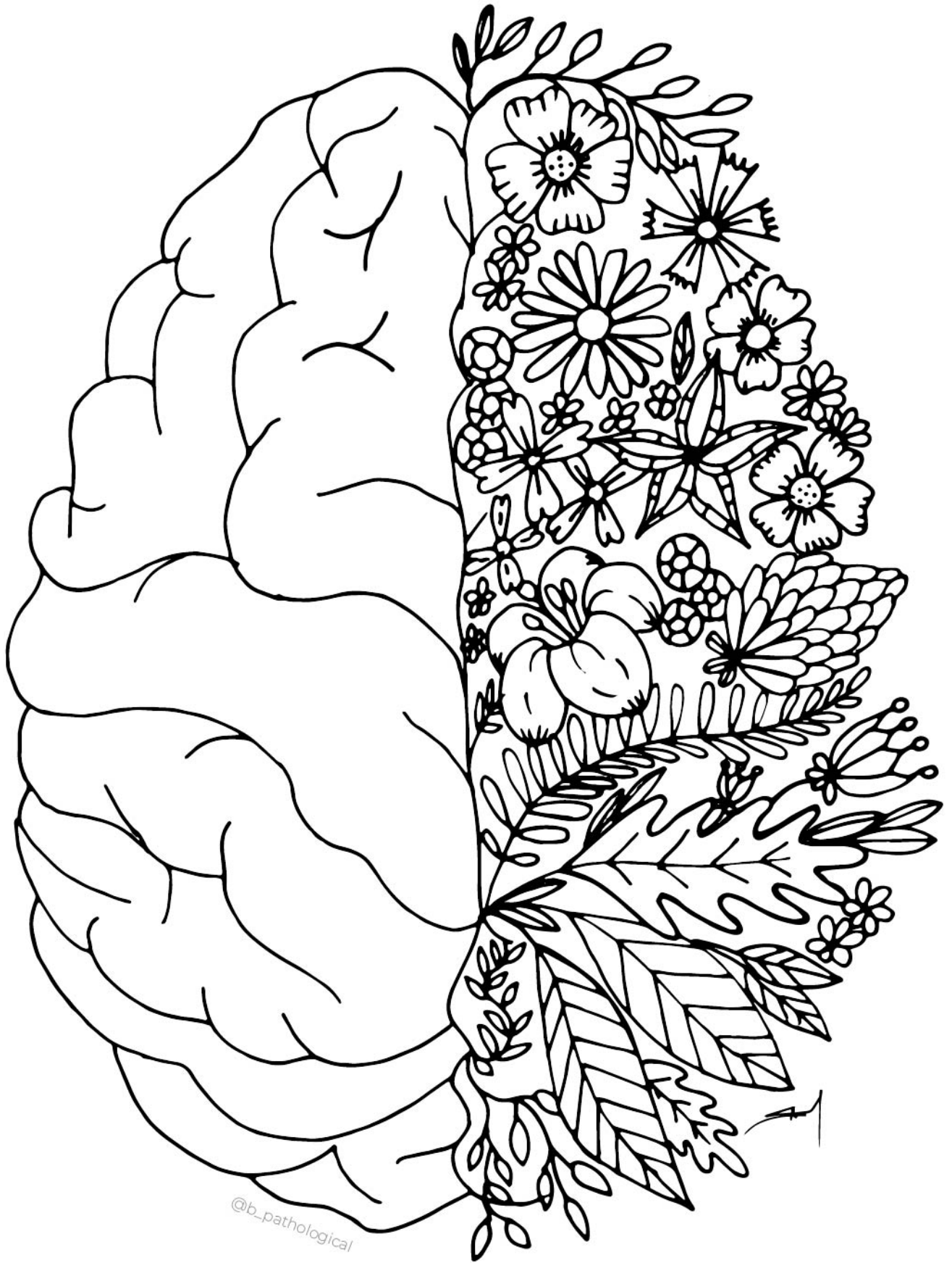


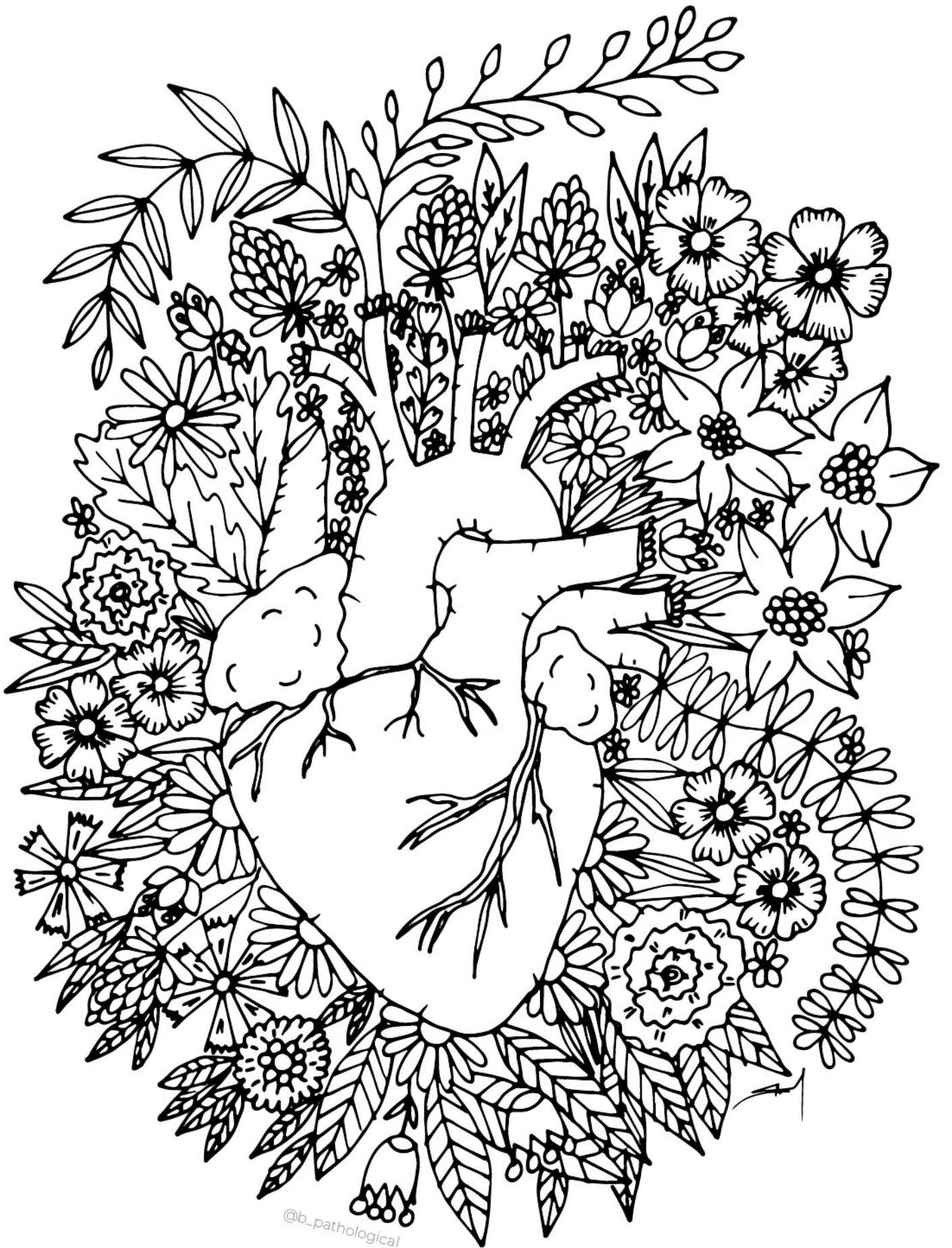




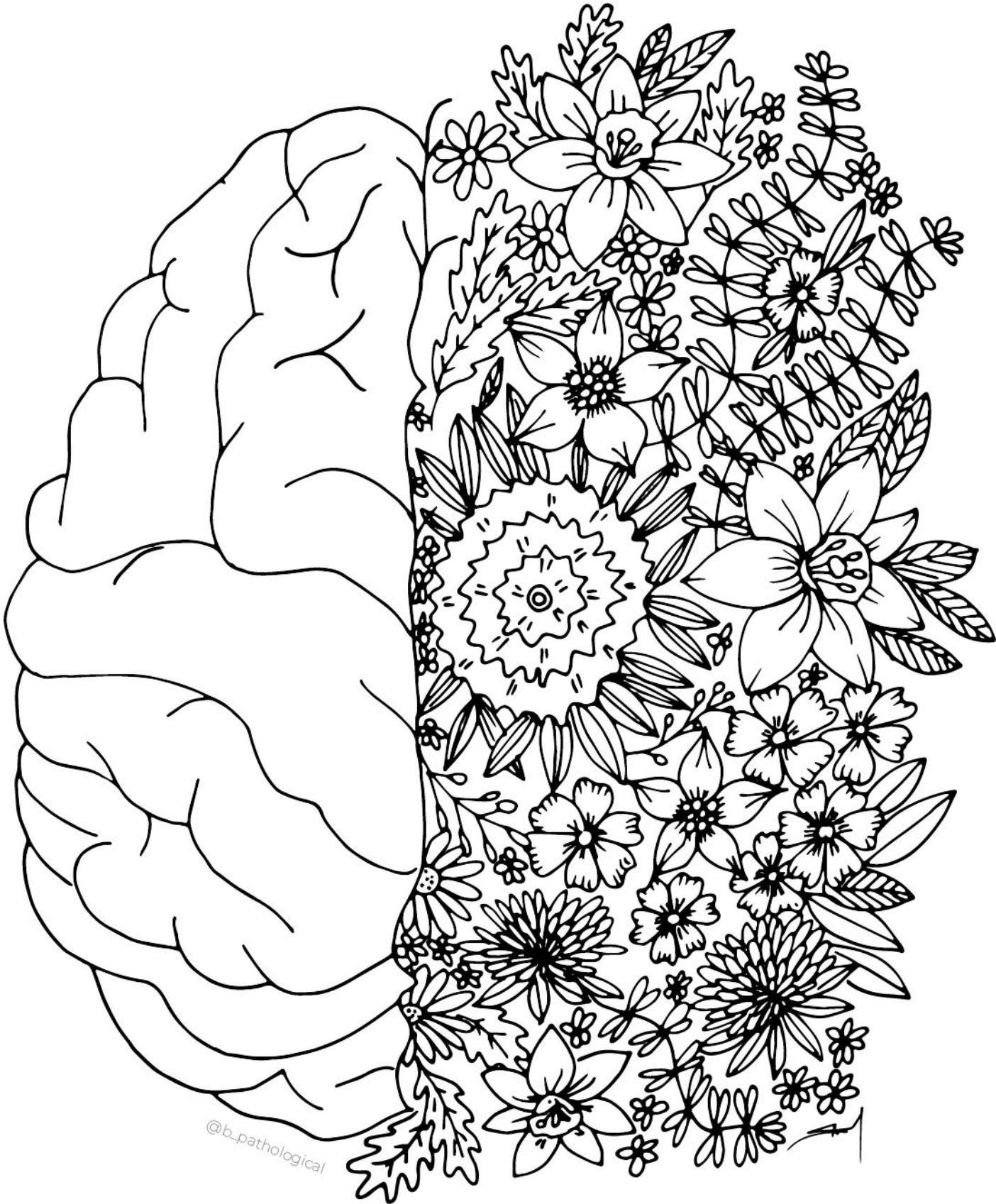









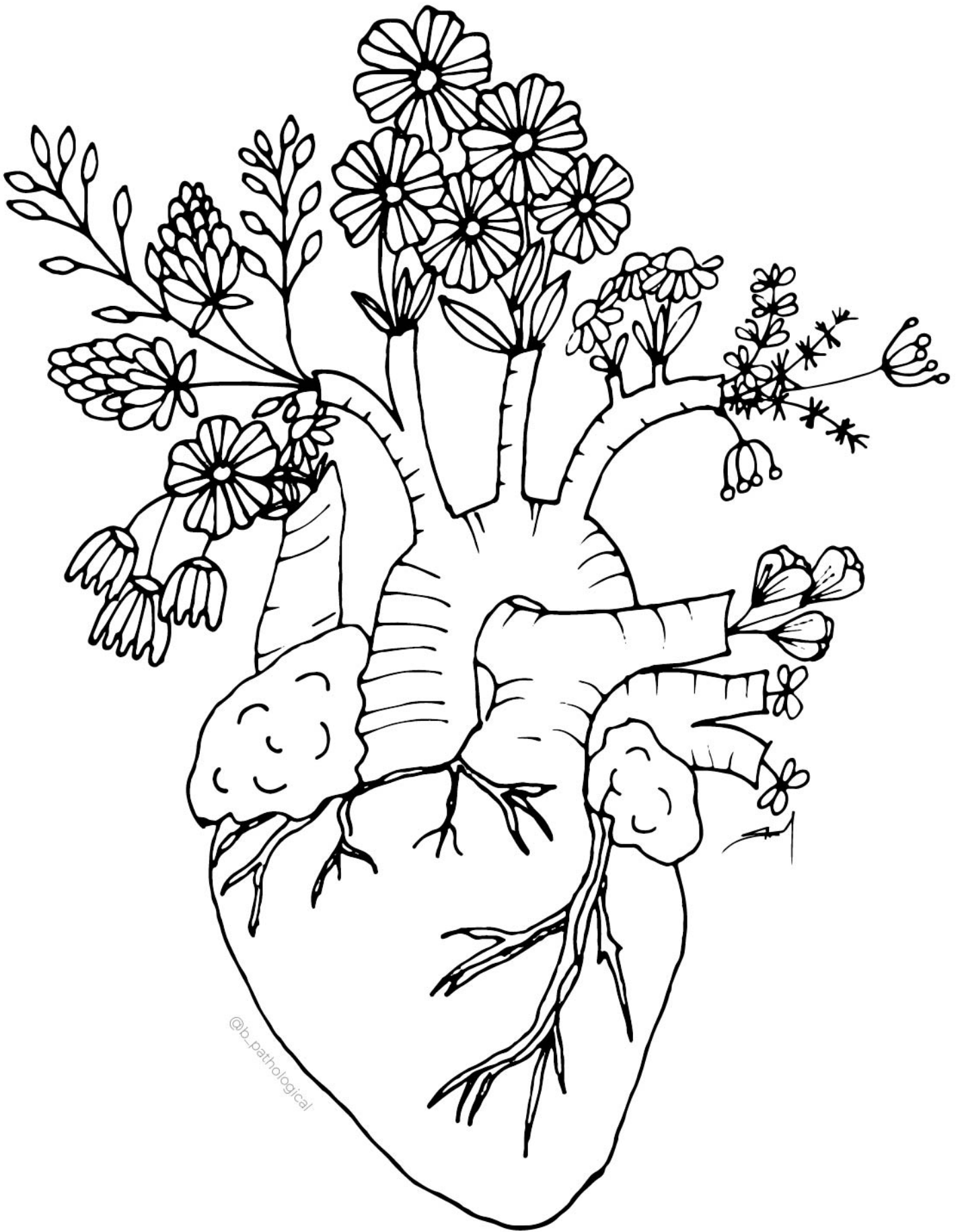




@b\_pathological

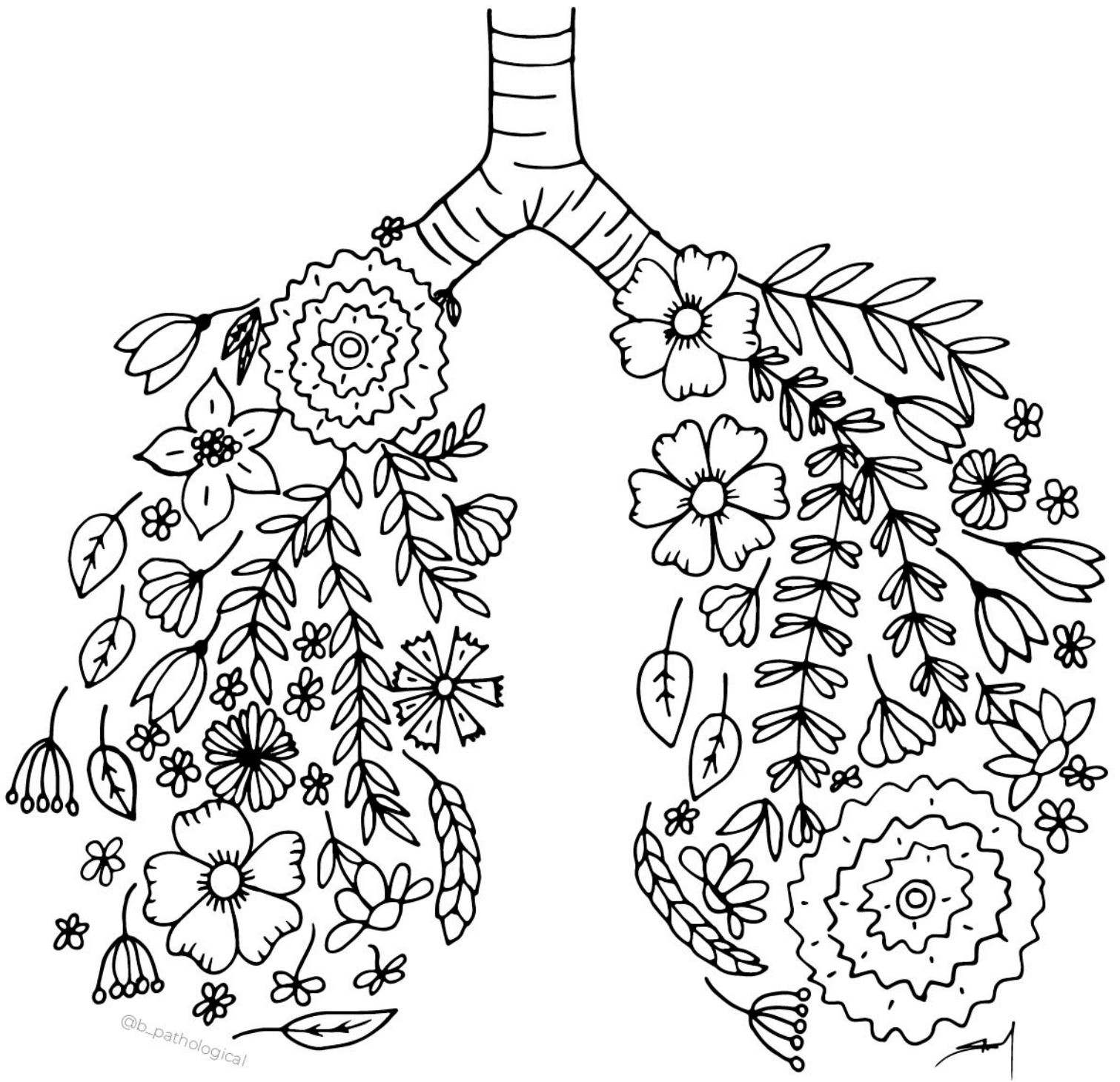


@b\_pathological





@b\_pathological




@b\_pathological





@b\_pathological

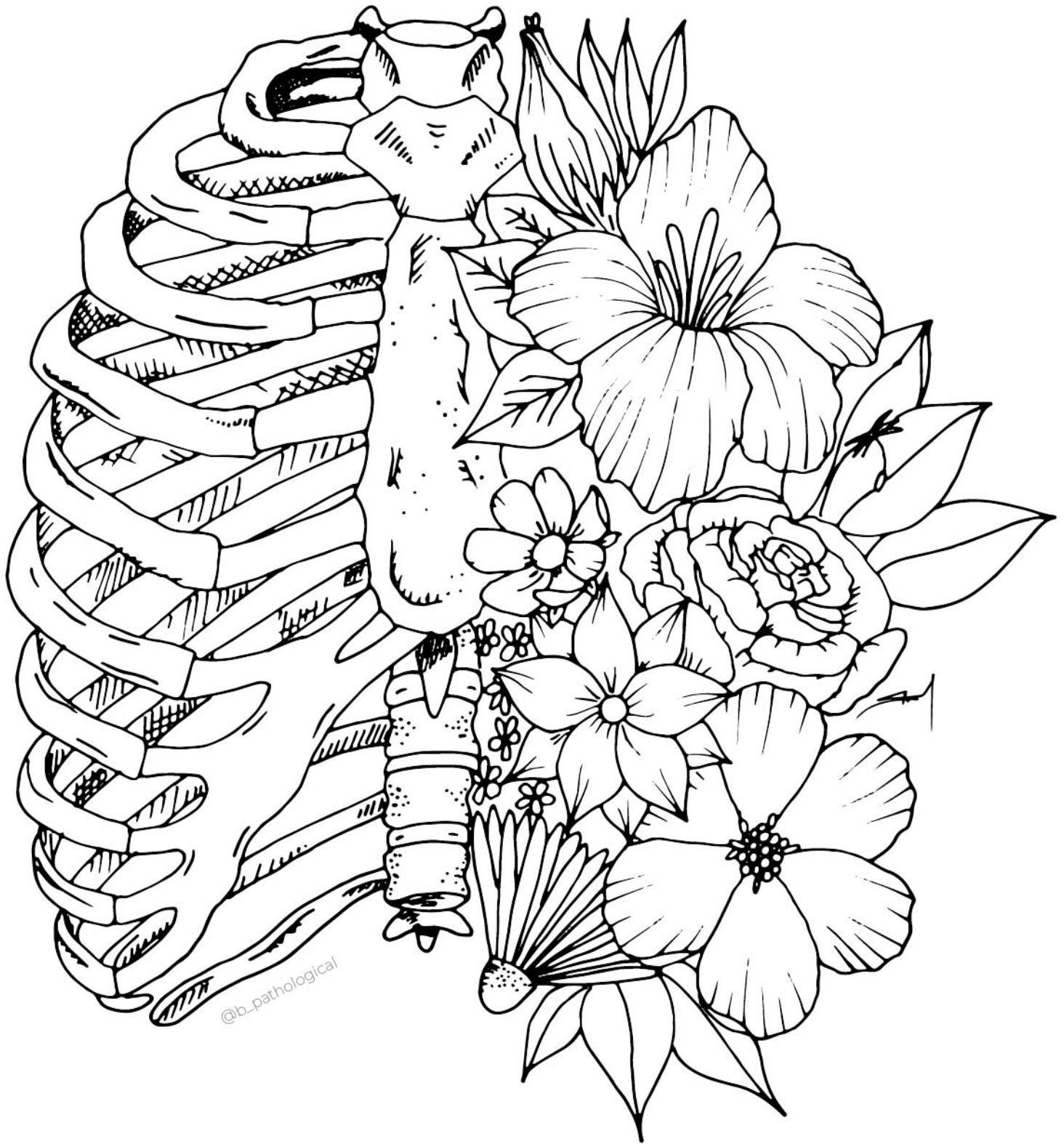





@b\_pathological



@b\_pathological

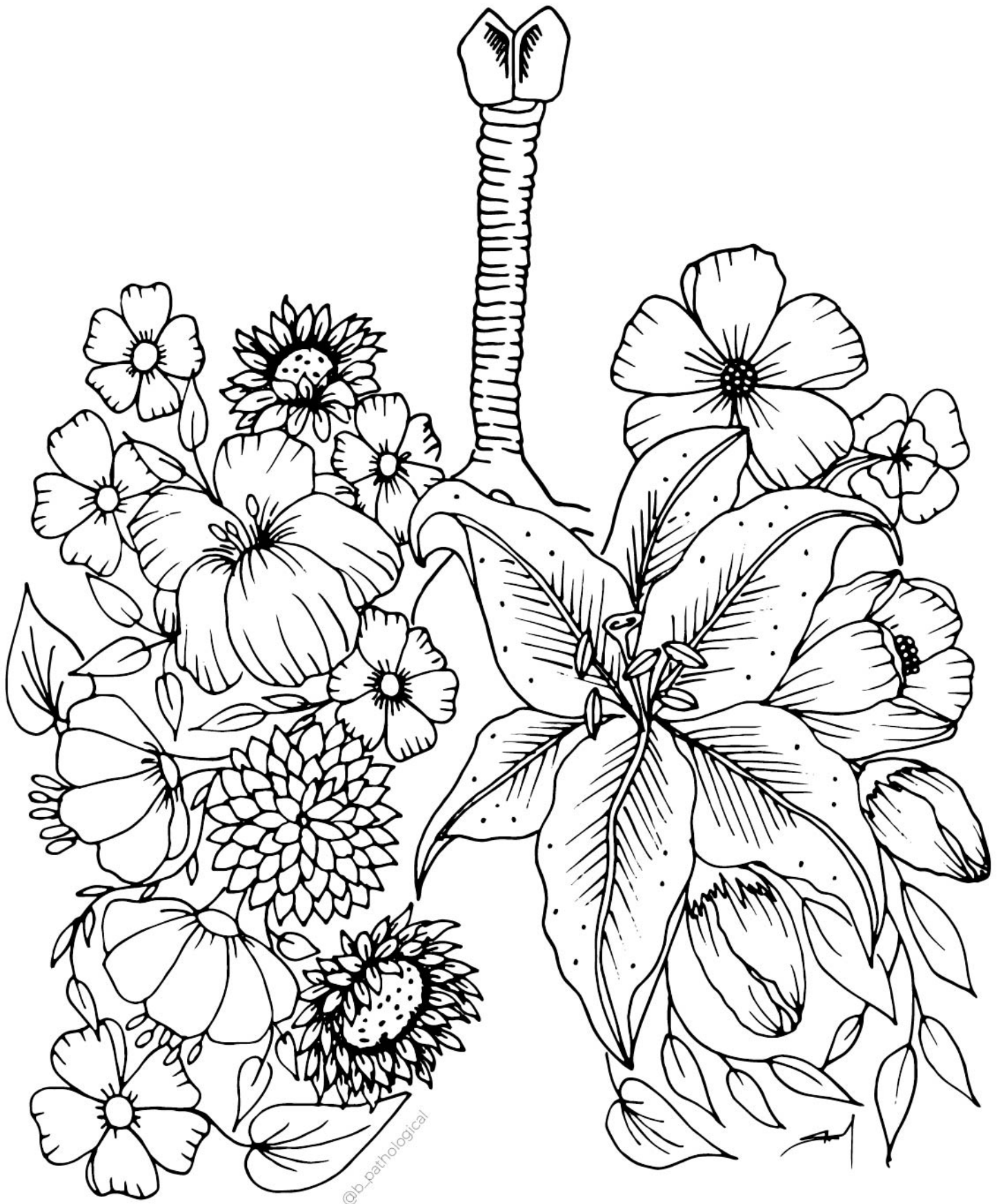




@b\_pathological








@b\_pathological








@b\_pathological



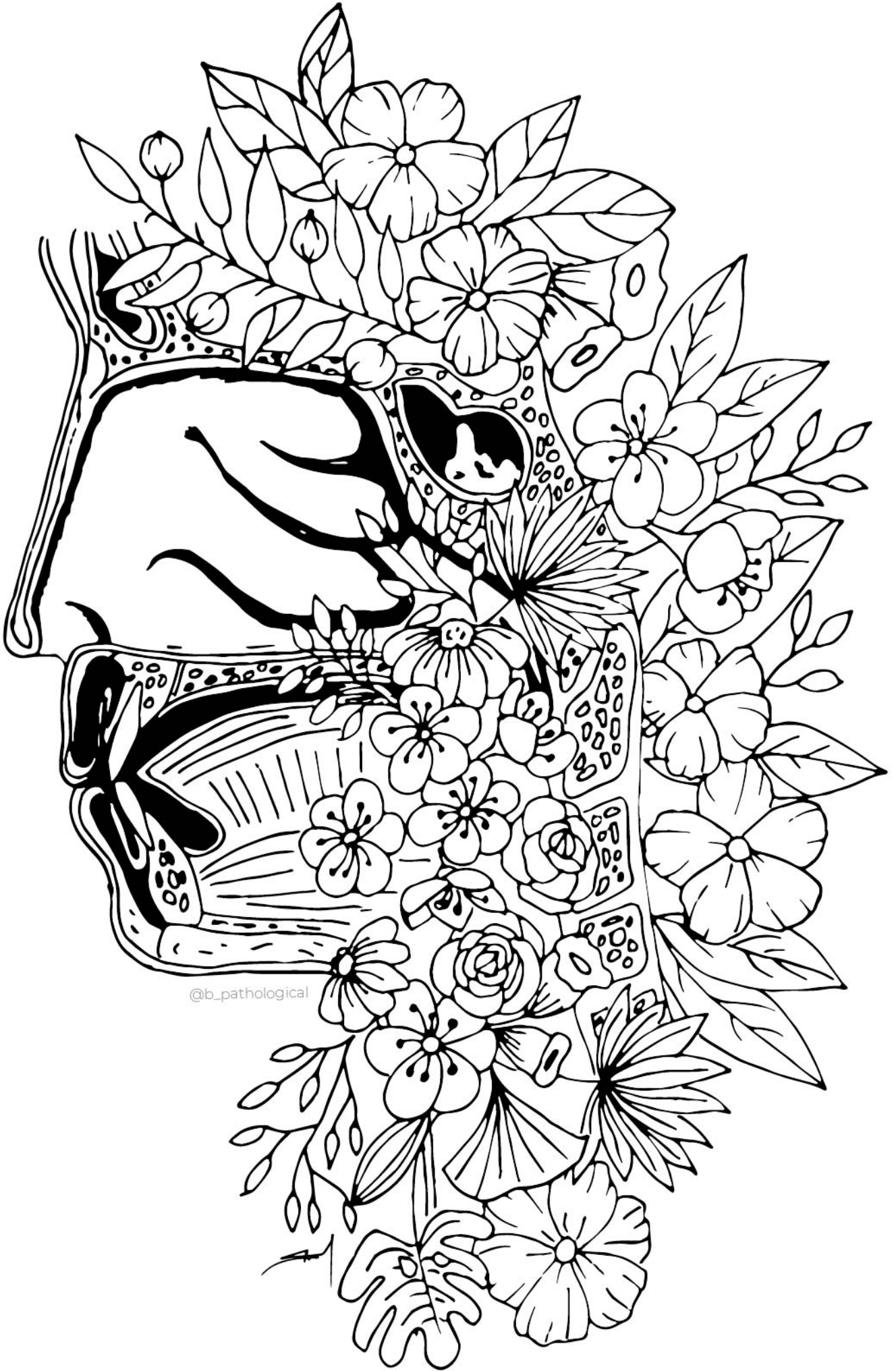
@b\_pathological



©-parthoigical







@b\_pathological



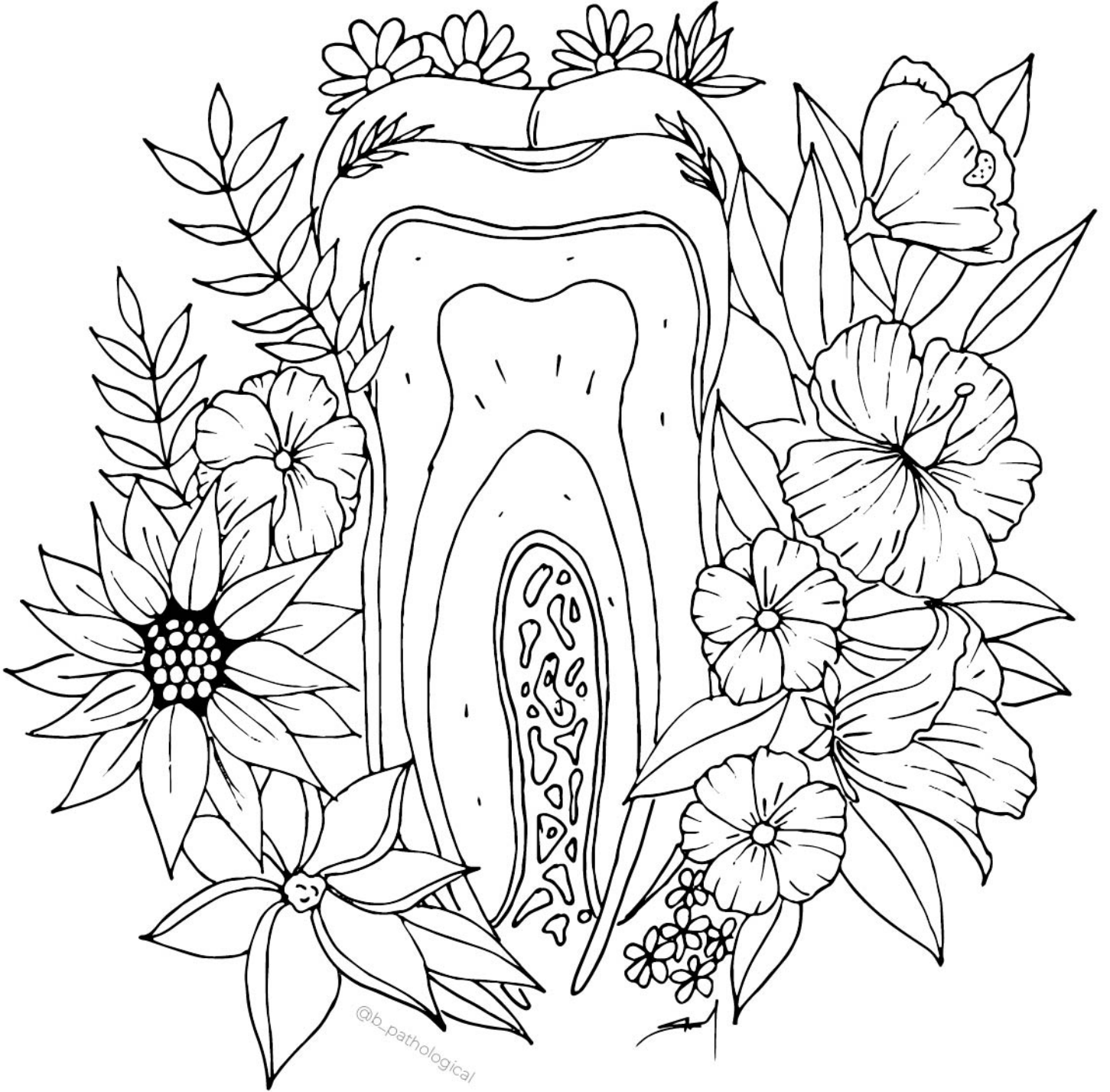

@b\_pathological









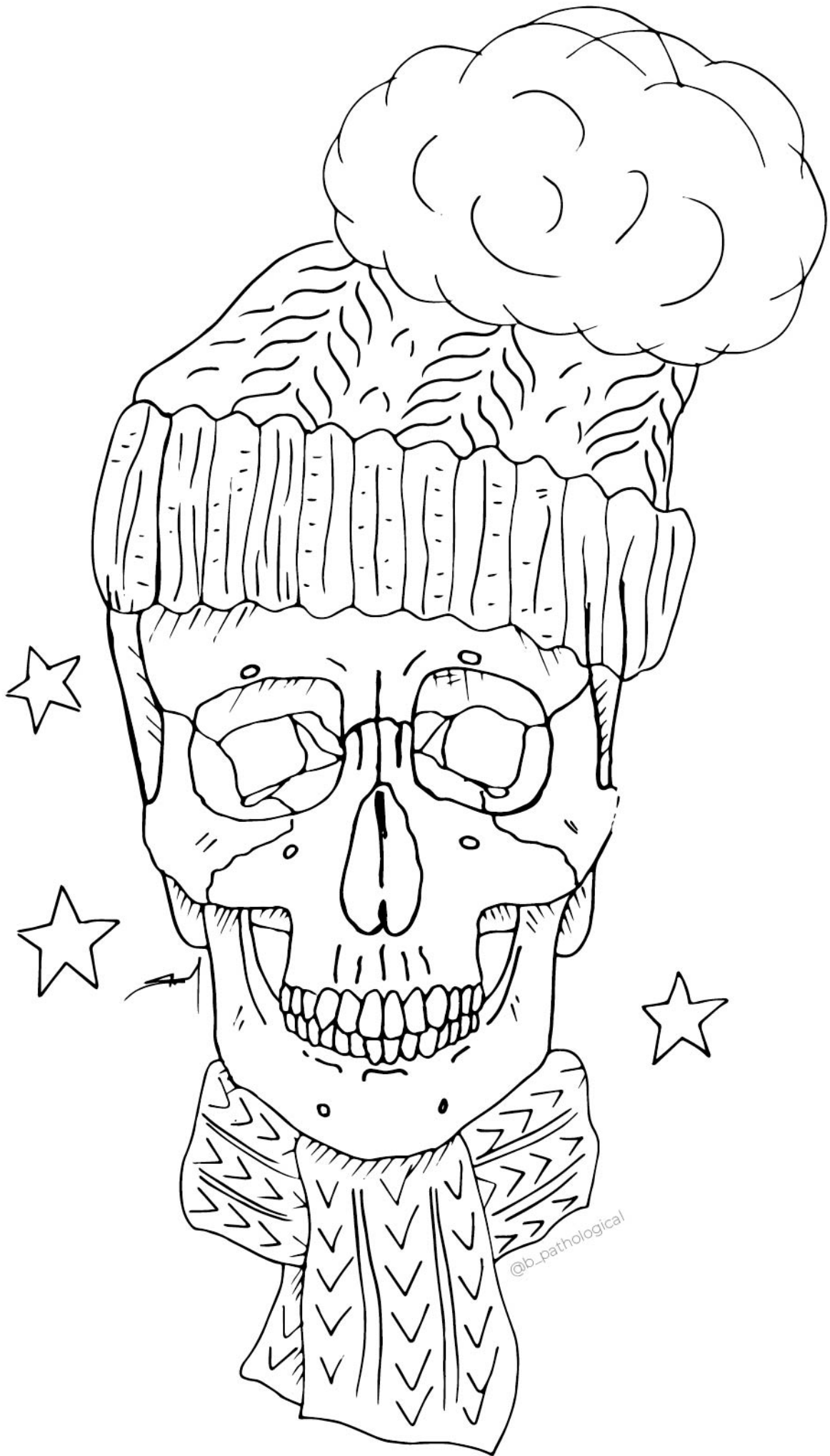







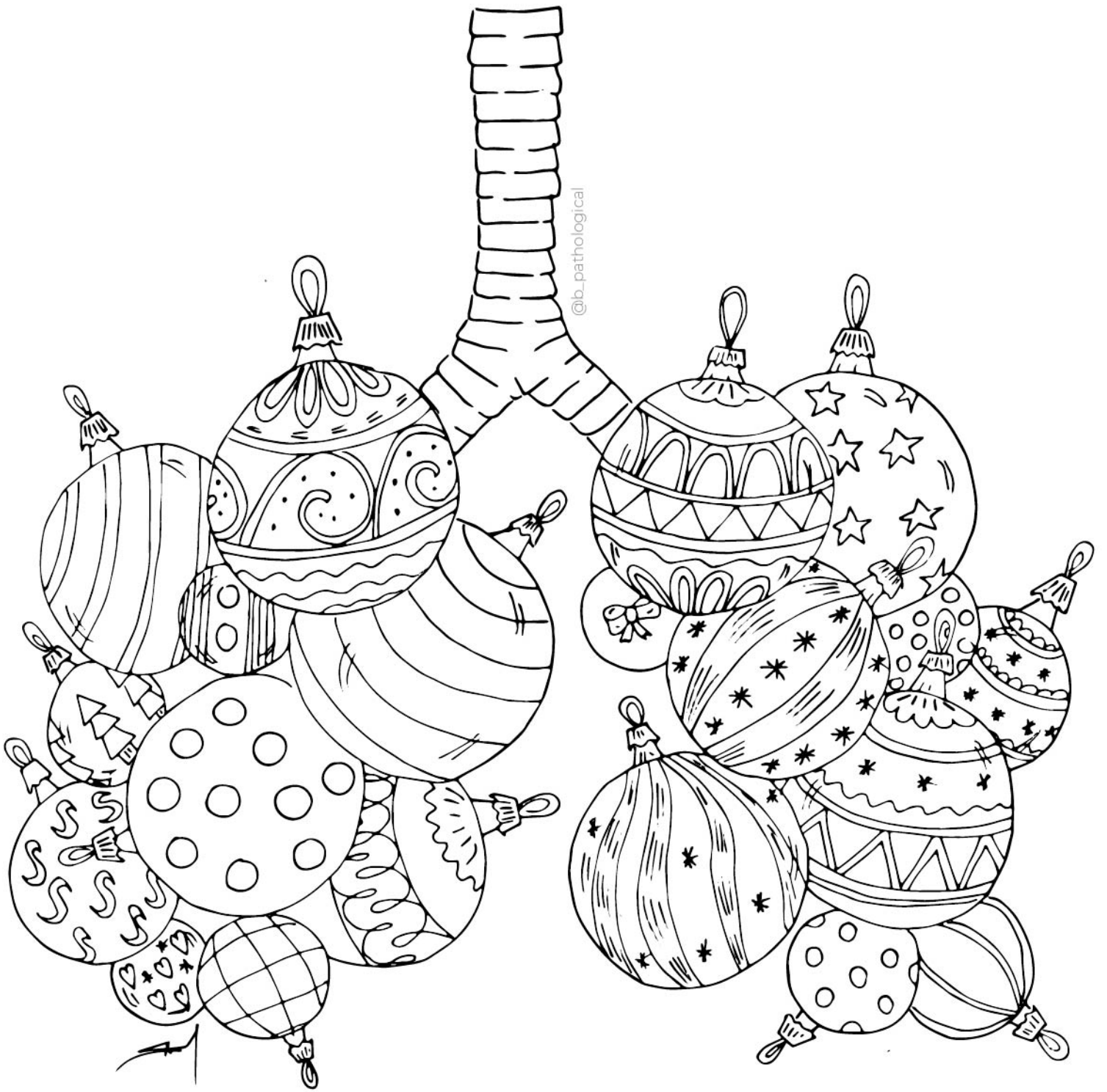
@b\_pathological













# **ANATOMICKÉ** OMALOŽOVÁNKY

@b\_pathological

© 2022